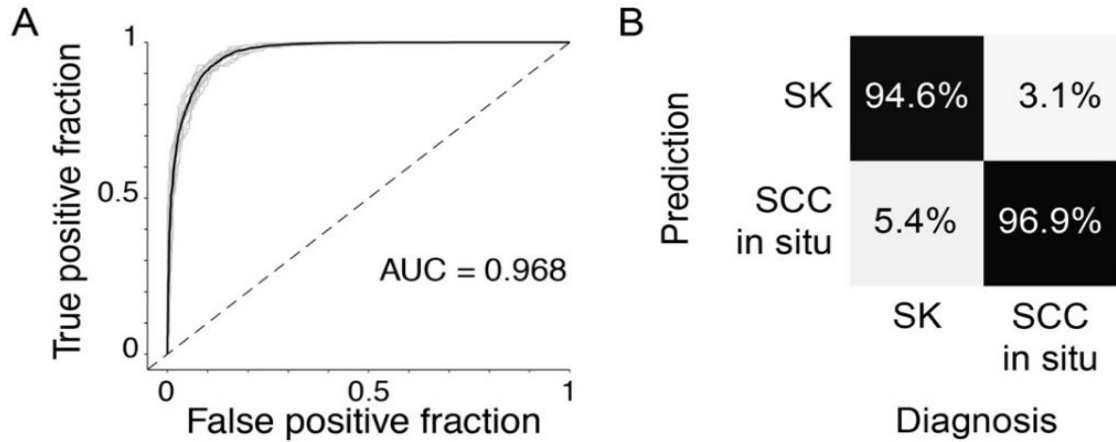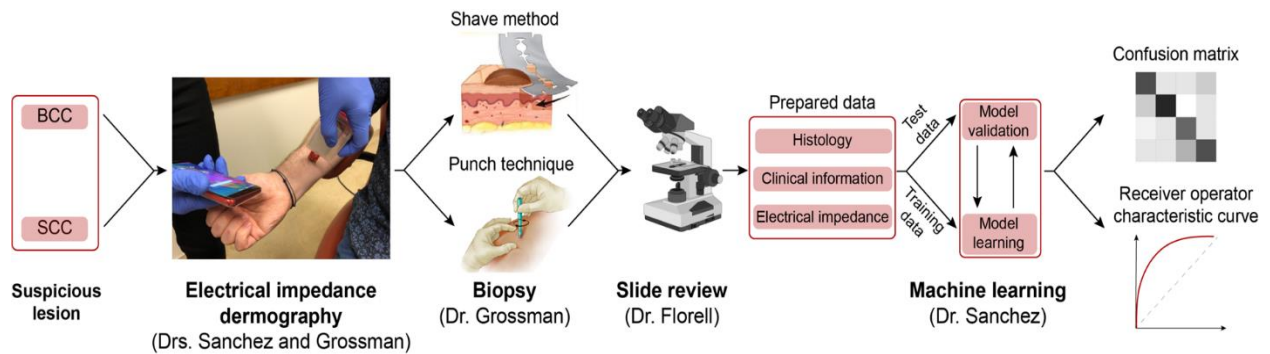


**Fig. 1:** (A) Receiver operator curve and (B) confusion matrix of Machine Learning algorithm diagnosing SCC-in-situ and inflamed SK. Data from Wong et al. (4).



**Fig. 2: Overview of experimental plan.** Clinically suspicious lesions will be measured by EID using URSKIN prior to biopsy, and then clinical and histologic information will be incorporated into the analysis.